

Regrowth and Fatal Rerupture Despite Proximal Occlusion After Coil Embolization of a Ruptured Large Basilar Bifurcation Aneurysm

—Case Report—

Toshihiro YASUI, Masaki KOMIYAMA, Yoshiyasu IWAI, Kazuhiro YAMANAKA, Yasuhiro MATSUSAKA, Toshie MORIKAWA, and Tomoya ISHIGURO

Department of Neurosurgery, Osaka City General Hospital, Osaka

Abstract

A 40-year-old man suffered chronic progressive symptoms of brainstem compression after undergoing endosaccular coil placement in a ruptured large basilar bifurcation aneurysm. Radiographical examinations showed coil compaction and regrowth of the aneurysmal mass with perifocal mesencephalic edema. The symptoms did not resolve even after additional clip occlusion of the upper basilar artery and the patient died of rerupture. At present, direct surgical clipping using a skull base technique with or without hypothermic circulatory arrest or upper basilar artery occlusion with or without bypass surgery may be a better choice as an initial treatment for giant or large basilar bifurcation aneurysm with a wide neck.

Key words: basilar bifurcation aneurysm, embolization, regrowth, rerupture, proximal occlusion

Introduction

Guglielmi detachable coil (GDC) embolization is increasingly used for the treatment of unclippable intracranial aneurysms, but the results of GDC embolization for the treatment of giant and very large aneurysms are far from satisfactory.^{2,4)} Half of the patients with giant aneurysms treated by GDC embolization either died or worsened neurologically.⁴⁾ We report a case of ruptured large basilar bifurcation aneurysm in which GDC embolization was initially successful, but follow-up angiography showed recanalization and massive aneurysm regrowth with brainstem compression. The symptoms of brainstem compression did not resolve despite additional upper basilar artery (BA) clip occlusion, and the patient died of rerupture.

Case Report

A 40-year-old man presented with Hunt and Hess grade II subarachnoid hemorrhage (SAH) at a local hospital. Computed tomography revealed Fisher group 3 SAH. Cerebral angiography demonstrated a

large basilar bifurcation aneurysm with a wide neck, high position, and posterior orientation (Fig. 1A). This very difficult surgical case was referred to our hospital for appropriate treatment on the day of rupture.

A right pterional approach with resection of the zygomatic arch was performed on the day of rupture. Surgical exploration found the aneurysm had a wide neck with tight adhesion of the thalamoperforating arteries that prevented surgical clipping. The aneurysm was wrapped in Bemsheet soaked in fibrin glue. Immediately after the surgery, the aneurysm was treated by the endovascular technique using interlocking detachable coils under general anesthesia. About 80% occlusion of the aneurysm was achieved (Fig. 1B). The patient made a complete recovery and was neurologically intact. However, follow-up angiography performed 3 months after the initial embolization showed coil compaction (Fig. 1C), so repeat embolization with GDCs was performed. Coil compaction and additional embolization were repeated twice during the following 5 years. However, follow-up examinations suggested aneurysm growth, rather than simple recanalization and coil compaction (Fig. 1D). He remained well for 5 years but then presented

Received February 5, 2004; Accepted May 17, 2004

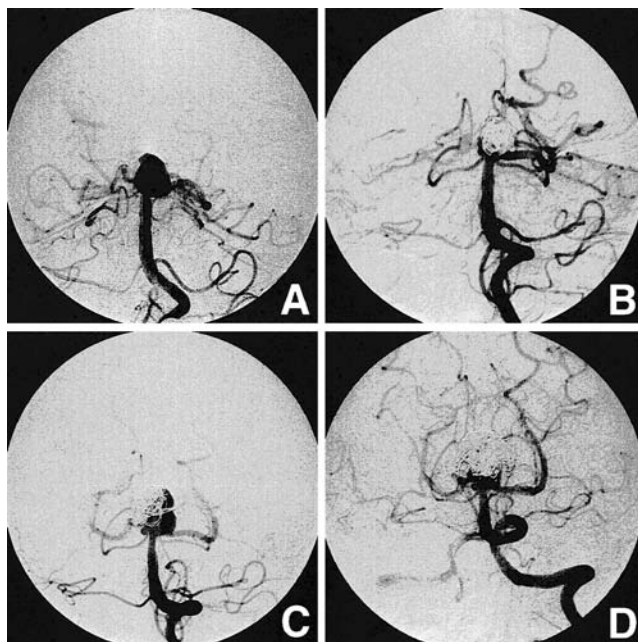


Fig. 1 Vertebral angiograms, anteroposterior view. **A:** Before surgery demonstrating a large and high position basilar bifurcation aneurysm projecting posteriorly. **B:** Just after coil embolization showing 80% occlusion of the aneurysm lumen. **C:** Three months after coil embolization revealing coil compaction. **D:** Five years after the initial coil occlusion showing aneurysm regrowth rather than simple recanalization.

with lethargy, left third cranial nerve paresis, and poor physical activity. Magnetic resonance (MR) imaging obtained 4 years after the initial surgery showed coil compaction within the basilar bifurcation aneurysm and severe midbrain compression with perifocal mesencephalic and thalamic edema (Fig. 2). A 2-week course of high-dose intravenously administered steroids failed to evoke a positive response.

We decided to treat the recurrent lesion by craniotomy to prevent subsequent rupture or enlargement 6 years after the initial surgery because of the unpredictable outcome of GDC embolization, the wide neck of the aneurysm, and the risk of coil herniation into the basilar apex. Physical examination before surgery found low physical activity, lethargy, and left oculomotor nerve paresis. The large coil mass within the aneurysm cavity and the dense scar formation induced by the Bemsheet wrapping were expected to obscure the surgeon's view of the aneurysm neck, and so neck clipping of the lesion was thought to be very difficult even with the assistance of hypothermic circulatory arrest.

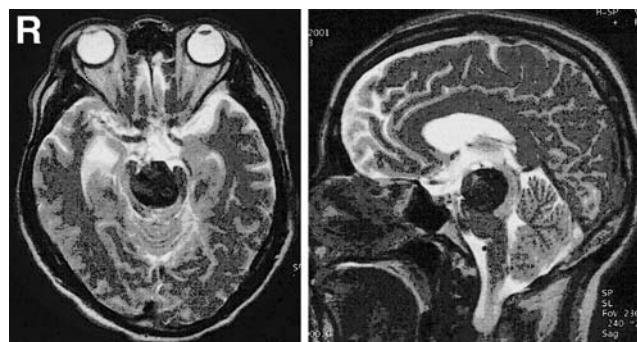


Fig. 2 Axial (left) and sagittal (right) T₂-weighted magnetic resonance images 4 years after the initial embolization demonstrating a basilar bifurcation aneurysm with coil compaction extending into the upper midbrain. Note the brainstem edema adjacent to the aneurysm.

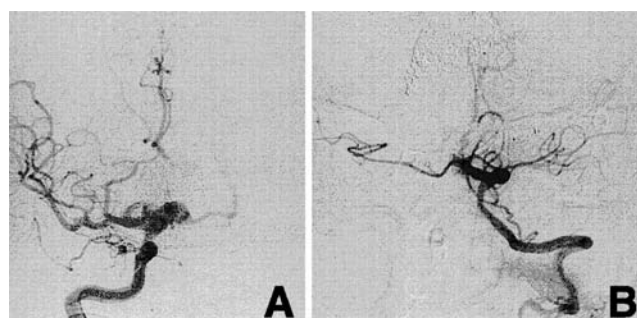


Fig. 3 Postoperative angiograms. **A:** Right carotid angiogram, anteroposterior view, demonstrating the posterior communicating artery supply to the posterior circulation, including retrograde filling of the ectatic aneurysmal base where the bilateral posterior cerebral arteries emerge. **B:** Left vertebral angiogram, anteroposterior view, after clip occlusion of the upper basilar artery.

Temporary trial balloon occlusion of the BA just proximal to the bilateral superior cerebellar arteries (SCAs) was well tolerated. Therefore, proximal clip occlusion of the upper BA was performed just proximal to the bilateral SCAs via a subtemporal approach.

The postoperative course was uneventful and the patient was neurologically unchanged for 3 days after the surgery. However, pontine infarction developed 4 days postocclusion, probably due to thrombotic occlusion of a perforating artery just proximal to the applied clip, and the patient fell into a locked-in state. Postoperative angiography one month after the BA occlusion revealed complete

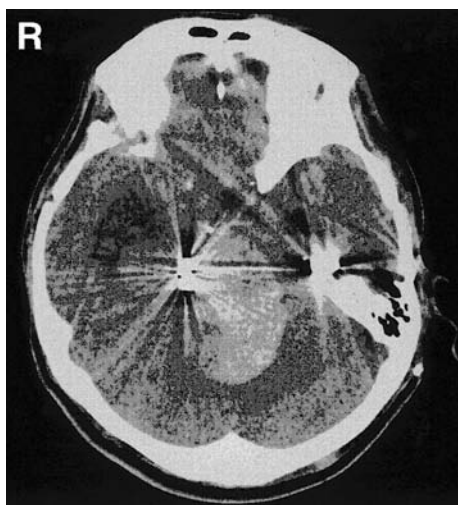


Fig. 4 Computed tomography scan showing massive hemorrhage concentrating around the aneurysm.

occlusion of the upper BA and contrast filling of only the base of the aneurysm, where the bilateral posterior cerebral arteries emerged (Fig. 3). Postoperative MR imaging 7 months after occlusion of the BA showed no reduction in the aneurysmal mass, and 9 months later the patient died of aneurysm rerupture (Fig. 4).

Discussion

The optimum treatment of intracranial aneurysms is direct clipping of the aneurysm neck to prevent subsequent rupture or enlargement. Unfortunately, open surgical treatment of a giant or very large basilar bifurcation aneurysm carries very high risks of morbidity and mortality. Recently, GDC embolization has been increasingly used in selected cases in which direct surgical clipping was undesirable or unfeasible like giant or very large basilar bifurcation aneurysms. However, GDC embolization of giant aneurysms is not as effective as in small or large aneurysms.⁴⁾ Coil compaction or regrowth is the greatest problem with GDC embolization of giant aneurysms.^{5,6)} Additional endosaccular coil placement in the recanalized aneurysm should not be performed because of the risk of worsening the mass effect on the brainstem.^{6,10)} Neural compression due to GDCs in combination with the “water-hammer” effect from the parent artery blood flow may have caused the neurological deterioration and progressive midbrain edema in our patient.³⁾

Worsening mass effect resulting from a coil-thrombus complex may be successfully treated by

BA occlusion.⁶⁾ Indeed, upper BA occlusion is a good choice for the treatment of difficult basilar bifurcation aneurysms. However, early postoperative thromboembolic brainstem ischemia within a week could develop and the mass effect might persist despite complete thrombosis of the aneurysm.⁸⁾ Our case suggests that upper BA occlusion does not guarantee prevention of rebleeding or regrowth of the giant basilar bifurcation aneurysm containing a large coil mass and thrombus. GDC treatment may secure a ruptured large or giant basilar bifurcation aneurysm in the short term, but does not provide adequate long-term protection without further intervention.^{1,9)} At present, direct surgical clipping using a skull base technique with or without hypothermic circulatory arrest⁷⁾ or upper BA occlusion with or without bypass surgery⁸⁾ may be a better choice as an initial treatment for giant or large basilar bifurcation aneurysm with a wide neck.

References

- 1) Byrne JV, Hubbard N, Morris JH: Endovascular coil occlusion of experimental aneurysms: Partial treatment does not prevent subsequent rupture. *Neurol Res* 16: 425-427, 1994
- 2) Gruber A, Killer M, Bavinski G, Richling B: Clinical and angiographic results of endosaccular coil treatment of giant and very large intracranial aneurysms: a 7-year, single-center experience. *Neurosurgery* 45: 793-804, 1999
- 3) Kwan ES, Heilman CB, Shucart WA, Klucznik RP: Enlargement of basilar artery aneurysms following balloon occlusion — “water-hammer effect.” Report of two cases. *J Neurosurg* 75: 963-968, 1991
- 4) Malisch TW, Guglielmi G, Vinuela F, Duckwiler G, Gobin YP, Martin NA, Frazee JC: Intracranial aneurysms treated with the Guglielmi detachable coil: midterm clinical results in a consecutive series of 100 patients. *J Neurosurg* 87: 176-183, 1997
- 5) Mericle RA, Wakhloo AK, Lopes DK, Lanzino G, Guterman LR, Hopkins LN: Delayed aneurysm regrowth and recanalization after Guglielmi detachable coil treatment. Case report. *J Neurosurg* 89: 142-145, 1998
- 6) Russell SM, Nelson PK, Jafar JJ: Neurological deterioration after coil embolization of a giant basilar apex aneurysm with resolution following parent artery clip ligation. Case report and review of the literature. *J Neurosurg* 97: 705-708, 2002
- 7) Spetzler RF, Hadley MN, Ligamonti D, Carter LP, Raudzens PA, Shedd SA, Wilkinson E: Aneurysms of the basilar artery treated with circulatory arrest, hypothermia, and barbiturate cerebral protection. *J Neurosurg* 68: 868-879, 1988
- 8) Steinberg GK, Drake CG, Peerless SJ: Deliberate basilar or vertebral artery occlusion in the treatment of intracranial aneurysms. Immediate results and

- long-term outcome in 201 patients. *J Neurosurg* 79: 161-173, 1993
- 9) Strother CM, Lunde S, Graves V, Toutant S, Hieshima GB: Late paraophthalmic aneurysm rupture following endovascular treatment. Case report. *J Neurosurg* 71: 777-780, 1989
- 10) Tsuura M, Terada T, Nakamura Y, Nakai K, Itakura T: Magnetic resonance signal intensity and volume changes after endovascular treatment of intracranial aneurysms causing mass effect. *Neuroradiology* 40: 184-188, 1998

Address reprint requests to: T. Yasui, M.D., Department of Neurosurgery, Osaka City General Hospital, 2-13-22 Miyakojima-Hondohri, Miyakojima-ku, Osaka 534-0021, Japan.
e-mail: yasui@msic.med.osaka-cu.ac.jp