

“Early” Apoplexy Due to Traumatic Intracranial Aneurysm

—Case Report—

Masaki KOMIYAMA, Toshie MORIKAWA, Hideki NAKAJIMA,
Toshihiro YASUI, and Masanori KAN*

*Department of Neurosurgery, and *Emergency and Critical Care Center,
Osaka City General Hospital, Osaka*

Abstract

A 76-year-old man presented with a traumatic aneurysm of the left internal carotid artery which caused repeated subarachnoid hemorrhages within 20 hours of a fall from a height. Early computed tomography (CT) detected no brain abnormalities, but repeat CT found subarachnoid hemorrhage. Internal carotid angiography detected a pseudoaneurysm, which was not treated because of his poor clinical condition. He died of multiple organ failure. Early detection of a traumatic intracranial aneurysm is important for the prevention of aneurysmal rupture, or “delayed” apoplexy. Review of 171 cases with traumatic aneurysms from the literature found that false negative angiography occurred only in three cases on post-trauma day 7 and thereafter. Early diagnostic angiography within a week of the initial trauma is indicated if traumatic aneurysm is suspected to detect early signs of irregularity, spasm, and narrowing of the arterial wall. Repeat angiography is indicated if aneurysmal formation is still highly suspected in spite of negative initial angiography.

Key words: diagnostic angiography, subarachnoid hemorrhage, timing of angiography, traumatic intracranial aneurysm

Introduction

The diagnosis of acute head trauma is now usually based on computed tomography (CT), and less frequently on cerebral angiography,^{52,55)} so that traumatic vascular lesions, including traumatic aneurysms and arteriovenous fistulas, may be overlooked. Traumatic intracranial aneurysm is a well-known cause of “delayed” apoplexy in patients with severe head trauma. Detection of such aneurysms is important because of the association with significant morbidity and mortality, and the aneurysm is essentially treatable if detected before becoming symptomatic. Detection of a traumatic intracranial aneurysm still depends on catheter cerebral angiography, but the optimal timing for the angiography is not yet elucidated. We present a case of traumatic intracranial aneurysm, which bled repeatedly in the early post-traumatic period, and discuss the optimal timing for diagnostic angiography to de-

tect such an aneurysm.

Case Presentation

A 76-year-old man attempted suicide by jumping from the top of a three-story building and was immediately transferred to our hospital. The Glasgow Coma Scale score on admission was 9. Profuse oro-nasal bleeding required immediate nasal packing and extensive facial laceration was treated by primary closure. His right upper and lower extremities showed marked swelling due to subcutaneous and intramuscular hemorrhage.

Initial CT of the brain showed only multiple skull base and facial bone fractures (Fig. 1A), but repeat CT performed 5 hours after the trauma showed thick subarachnoid hemorrhage in the left basal cistern (Fig. 1B). Follow-up CT at 15 hours after the trauma showed increased subarachnoid hemorrhage in the basal cistern (Fig. 1C). Continued oro-nasal bleeding refractory to nasal packing prompted endovascular treatment 18 hours after the trauma. Bilateral external carotid angiography showed marked vasocon-

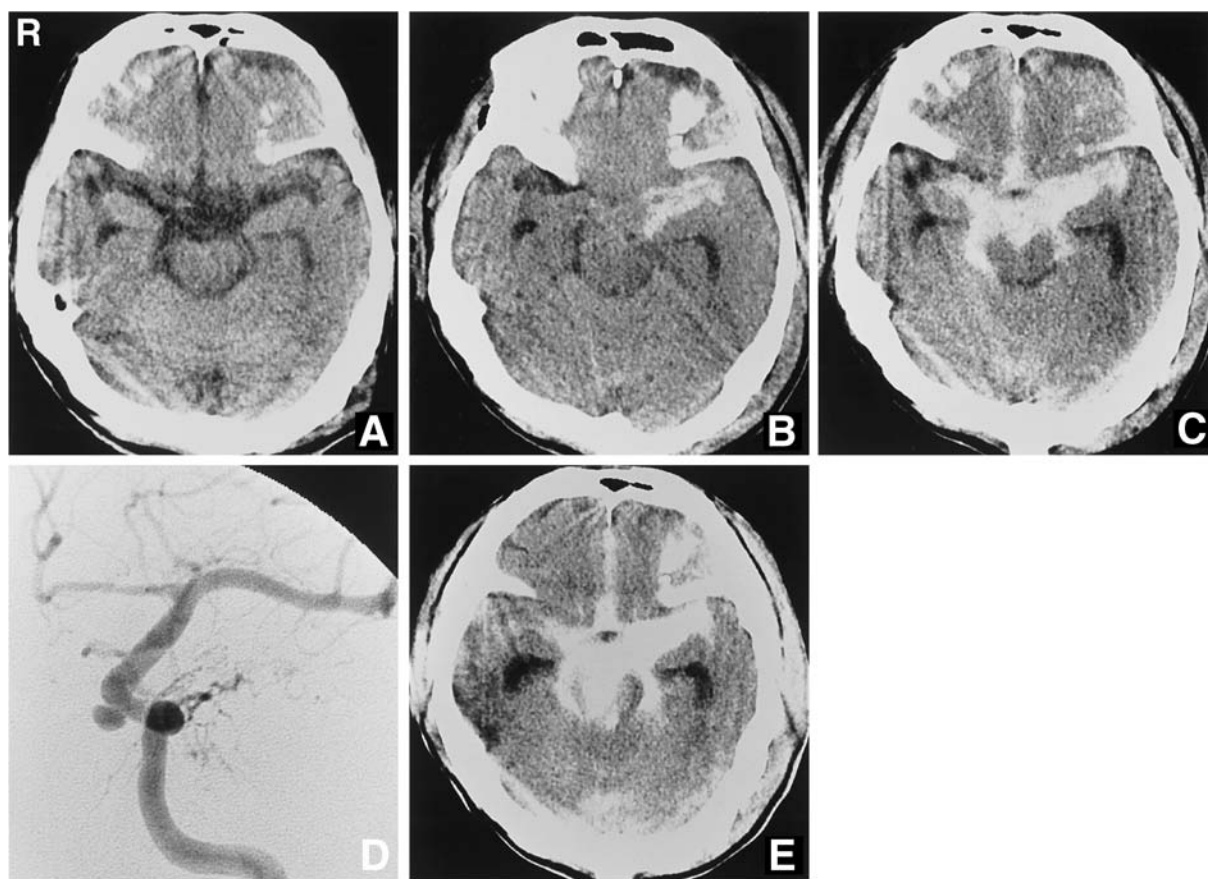


Fig. 1 Computed tomography (CT) scans performed immediately (A), 5 hours (B), and 15 hours after the trauma (C). The initial CT scan of the brain shows no abnormalities, but subsequent CT scans show increasing subarachnoid hemorrhage in the basal cistern. Digital subtraction angiogram, anteroposterior view, of the left internal carotid artery performed 18 hours after the trauma (D) showing a normal left middle cerebral artery and a traumatic aneurysm located immediately proximal to the origin of the ophthalmic artery. CT scan performed after angiography (20 hours after the trauma) (E) showing further increase of the subarachnoid hemorrhage in the basal cistern, suggesting rerupture of the traumatic aneurysm.

striction due to hypovolemic hypotension, but no active bleeding was seen. Transarterial embolization in the external carotid system using polyvinyl alcohol particles and platinum coils was performed bilaterally. Left internal carotid angiography showed a normal left middle cerebral artery and an aneurysmal dilatation in the C₃ portion proximal to the ophthalmic artery (Fig. 1D). We thought that this aneurysmal dilatation was a pseudoaneurysm because of its vicinity to the skull base fracture and relatively rare location for the cerebral aneurysm. This pseudoaneurysm was left untreated due to the patient's poor medical condition. We thought that the oro-nasal bleeding did not originate at the aneurysm because bleeding had been continuous since admission and was not so profuse as bleeding from the laceration of the internal carotid artery.

However, we considered that rupture of the aneurysm had caused the subarachnoid hemorrhage through a dural laceration despite the C₃ location of the aneurysm. Oro-nasal bleeding was well controlled by embolization, but post-intervention CT at 20 hours after the trauma showed a further increase of the subarachnoid hemorrhage in the basal cistern, indicating rerupture of the aneurysm (Fig. 1E). The condition of the patient deteriorated without evidence of further rebleeding from the aneurysm on CT, and he died on post-trauma day 11 due to multiple organ failure. Autopsy was not performed.

Discussion

Traumatic aneurysms can be histologically classified as true, false, dissecting, or mixed based on the

damaged structures of the vascular wall. The adventitia is preserved in a true aneurysm. All wall structures are involved in a false aneurysm. Hemorrhage extends within the wall in a dissecting aneurysm. Coexistence of these types occurs in a mixed aneurysm.

Review of 171 cases reported after 1960, describing the interval from trauma to angiographic demonstration of an aneurysm and/or aneurysmal rupture, found 33 females (19.3%) and 138 males (80.7%), aged from 6 weeks to 76 years (mean 30.1 years). The age distribution is shown in Fig. 2. Direct injury occurred in 115 cases (67.3%), including 30 penetrating injuries and 16 iatrogenic injuries, whereas indirect injury occurred in 55 cases (32.2%). Epistaxis occurred in 25 cases (14.6%), intracranial hemorrhage in 82 cases (48.0%), and mass effect in eight cases (4.7%). Concomitant traumatic arteriovenous fistula was observed in 12 cases, among which carotid-cavernous sinus fistula was observed in 10 cases.^{3,7,21,27,35,38,42,53,57,76,81} Overall mortality was 18.1%.

The traumatic aneurysms were located in the intradural portion (mostly the supraclinoid portion) of the internal carotid artery in 24 cases,^{7,20,24,34,38,47,51,55,59,65,71,76,78,81,84-86} in the cavernous portion of the internal carotid artery in 35 cases,^{4,7,8,10,23,26,27,33,42,44,49,57,58,61,62,64,70,71,76,78,81,82,84,85} in the petrous portion of the internal carotid artery in four cases,^{7,11,78} on the ophthalmic artery in two cases,^{1,60} on the proximal anterior cerebral artery in five cases,^{3,31,35,46,53} on the distal anterior cerebral artery in 43 cases,^{1-3,5,7,19,21-23,30,32,34,40,41,43,48,50,52,62,66,69,72,74,79-81,85} on the anterior communicating artery in one case,¹³ on the anterior choroidal artery in one case,¹⁵ on the proximal middle cerebral artery in three cases,^{14,16,28} on the distal middle cerebral artery in 32 cases,^{1,2,7,8,18,22,23,25,34-37,55,61-63,68,73,75,80} on the posterior cerebral artery in two cases,^{9,35} on the vertebral artery in one case,⁵⁶ on the basilar artery in two cases,^{6,35} on the superior cerebellar arteries in two cases,^{12,21} on the posterior inferior cerebellar artery in six cases,^{45,67,77,83} and on the middle meningeal artery in 11 cases.^{29,35,39,50,54,55,61}

The timing of angiographic demonstration of the aneurysm and/or aneurysmal rupture is shown in Fig. 3. Catheter angiography demonstrated a traumatic aneurysm on the day of trauma (day 0) in 20 cases,^{1,6,7,15,16,20-22,24,27,55,61,67,79} and as late as several years after trauma in six cases.^{8,12,14,76} False negative angiography occurred on day 0 in 17 cases,^{7,22-24,32,36,43,59,62,67,69,75,80,84,85} on day 1 in two cases,^{71,74} on day 2 in one case,¹ on day 3 in one case,⁸¹ on day 4 in two cases,^{3,28} on day 7 in one case,¹¹ on day 10 in one case,³⁷ and on day 80 in one case.³³

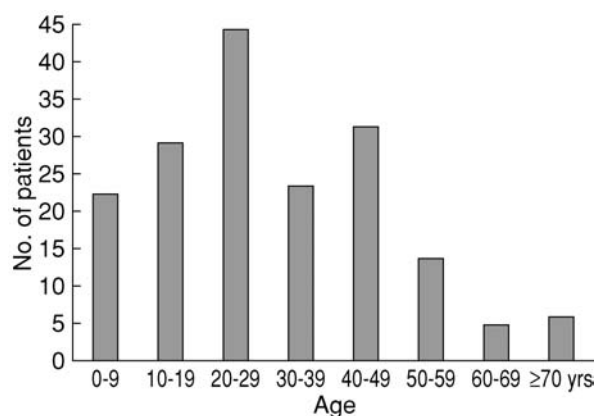


Fig. 2 Age distribution of patients with traumatic intracranial aneurysms.

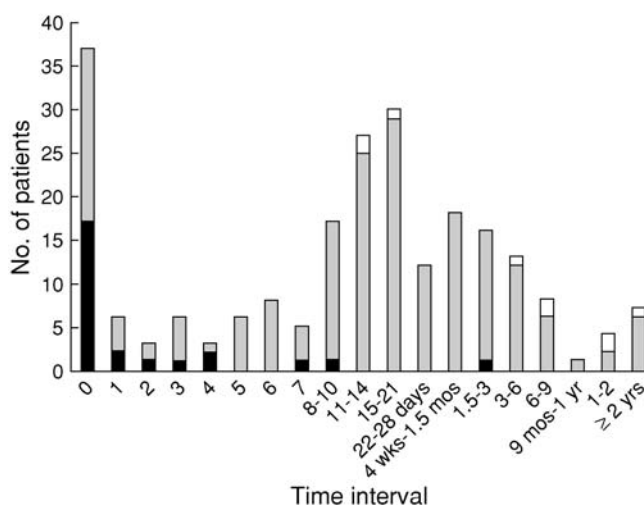


Fig. 3 Time interval from the trauma to the angiographic demonstration of traumatic intracranial aneurysm and/or rupture of the aneurysm. Closed bar indicates non-visualization of the aneurysm (false negative angiography). Stippled bar indicates angiographic visualization of the aneurysm and/or rupture of the aneurysm. Open bar indicates disappearance of the aneurysm detected by the initial angiography.

Spontaneous cure (disappearance) of the traumatic aneurysm, which had been demonstrated previously, occurred in nine cases between day 12 and 7 years from the trauma.^{7,25,48,50,61,63,80,85}

The angiographic features of traumatic intracranial aneurysm are delayed filling and emptying of the aneurysmal sac, irregular contour of the sac, absence of a clear neck, and an ostium not located at

the common arterial branching points.^{5,7,55)} False negative angiography on the first few days after trauma may indicate irregular arterial wall, spasm, and/or narrowing of the artery as early angiographic signs suggestive of subsequent aneurysmal formation.^{24,71,75,84)} Therefore, careful observation of these early signs is important if angiography fails to demonstrate an aneurysm in the early stage, and repeat angiography to detect aneurysmal formation is necessary. False negative angiography may also result from vasospasm due to subarachnoid hemorrhage, compression of the aneurysm by a surrounding hematoma, and thrombotic occlusion of the aneurysm.^{7,52,61)}

Traumatic intracranial aneurysm is associated with high morbidity and mortality, so early detection and treatment are important. Traumatic aneurysm should be suspected if fracture of the sphenoid sinus and/or carotid canal is observed, especially accompanied by epistaxis; if delayed subarachnoid hemorrhage, unexplained neurological deterioration, or progressive cranial nerve paresis is observed; if a juxtafalcine hematoma is observed; or if the trauma is a penetrating injury, especially resulting from a stab wound or gunshot wound.^{8,35,52,81)} Bleeding from traumatic aneurysm, called "delayed" apoplexy, has long been believed to occur about 2–3 weeks after the trauma. Routine angiography has been recommended at the beginning of the second week in all patients with suspected transcranial stab wounds.³⁷⁾ However, our review shows that bleeding can occur as early as within a few days, but occasionally after several months or years (Fig. 3). Therefore, determination of the optimal timing of diagnostic cerebral angiography for detection of traumatic aneurysms in the early and delayed stages is difficult. Early (not delayed) diagnostic angiography was advised in low-velocity penetrating wounds to the brain,¹⁷⁾ and acute-phase angiography detected traumatic aneurysms within 48 hours of injury in five of 12 patients with gunshot wounds.³⁵⁾ No false negative angiography was reported except for three cases with angiography performed later than day 7.^{11,33,37)}

The pathological process in the traumatized arterial wall may begin to develop immediately following the trauma. As shown in our case, traumatic aneurysm may be formed and bleed in the early stage. Such an occurrence is a diagnostic and therapeutic challenge because extremely early detection and immediate treatment may be required to prevent possible fatal bleeding. Failure to demonstrate an aneurysm on the initial angiography in the acute stage does not exclude the presence of a traumatic aneurysm. We recommend early diagnostic an-

giography within a week following stabilization from the initial traumatic insult, especially to detect the early signs of wall irregularity, narrowing, and spasm of the intracranial vasculature, and repeat angiography if aneurysmal formation is still highly suspected despite negative initial angiography.

References

- 1) Aarabi B: Traumatic aneurysms of brain due to high velocity missile head wounds. *Neurosurgery* 22: 1056–1063, 1988
- 2) Acosta C, Williams PE, Clark K: Traumatic aneurysms of the cerebral vessels. *J Neurosurg* 36: 531–536, 1972
- 3) Amagasa M, Onuma T, Suzuki J, Fujimoto S, Sakurai Y: [Traumatic anterior cerebral artery aneurysms. Experiences of 4 cases and review of the literature]. *No Shinkei Geka* 14: 1585–1592, 1986 (Jpn, with Eng abstract)
- 4) Araki C, Handa H, Handa J, Yoshida K: Traumatic aneurysm of the intracranial extradural portion of the internal carotid artery. *J Neurosurg* 23: 64–67, 1965
- 5) Asari S, Nakamura S, Yamada O, Beck H, Sugatani H, Higashi T: [Traumatic aneurysm of peripheral cerebral artery]. *No To Shinkei* 28: 793–805, 1976 (Jpn, with Eng abstract)
- 6) Bank WO, Nelson PB, Drayer BP, Wilkins RH, Rosenbaum AE: Traumatic aneurysm of the basilar artery. *AJR Am J Roentgenol* 130: 975–977, 1978
- 7) Benoit BG, Wortzman G: Traumatic cerebral aneurysms. Clinical features and natural history. *J Neurol Neurosurg Psychiatry* 36: 127–138, 1973
- 8) Buckingham MJ, Crone KR, Ball WS, Tomsick TA, Berger TS, Tew JM: Traumatic intracranial aneurysms in childhood: two cases and a review of the literature. *Neurosurgery* 22: 398–408, 1988
- 9) Burton C, Velasco F, Dorman J: Traumatic aneurysm of a peripheral cerebral artery. Review and case report. *J Neurosurg* 28: 468–474, 1968
- 10) Cabezudo JM, Carrillo R, Vaquero J, Areitio E, Martinez R: Intracavernous aneurysm of the carotid artery following transsphenoidal surgery. *J Neurosurg* 54: 118–121, 1981
- 11) Capanna AH: Traumatic intracranial aneurysm and Gradenigo's syndrome secondary to gunshot wound. *Surg Neurol* 22: 263–266, 1984
- 12) Cockrill HH, Jimenez JP, Goree JA: Traumatic false aneurysm of the superior cerebellar artery simulating posterior fossa tumor. Case report. *J Neurosurg* 46: 377–380, 1977
- 13) Cosgrove GR, Villemure JG, Melancon D: Traumatic intracranial aneurysm due to arterial injury at surgery. Case report. *J Neurosurg* 58: 291–294, 1983
- 14) Courville CB: Traumatic aneurysm of an intracranial artery. Description of lesion incident to a shotgun wound of the skull and brain. *Bull Los Ang Neurol Soc* 25: 48–54, 1960

- 15) Cressman MR, Hayes GJ: Traumatic aneurysm of the anterior choroidal artery. Case report. *J Neurosurg* 24: 102-104, 1966
- 16) Dittmore QM, Samson DS, Beyer CW: Traumatic middle cerebral artery aneurysm: case report. *Neurosurgery* 6: 293-296, 1980
- 17) du Treu MD, van Dellen JR: Penetrating stab wounds to the brain: the timing of angiography in patients presenting with the weapon already removed. *Neurosurgery* 31: 905-912, 1992
- 18) Eichler A, Story JL, Bennett DE, Galo MV: Traumatic aneurysm of a cerebral artery. Case report. *J Neurosurg* 31: 72-76, 1969
- 19) Endo S, Sato S, Uneoka K, Takaku A, Suzuki J: [Traumatic aneurysm of the callosomarginal artery: case report]. *No Shinkei Geka* 2: 329-336, 1974 (Jpn, with Eng abstract)
- 20) Enomoto H, Shibata T, Ito A, Harada T: Traumatic aneurysm of the supraclinoid internal carotid artery: report of a case. *Neurosurgery* 15: 700-702, 1984
- 21) Ferry DJ, Kempe LG: False aneurysm secondary to penetration of the brain through orbitofacial wounds. Report of two cases. *J Neurosurg* 36: 503-506, 1972
- 22) Fleischer AS, Patton JM, Tindall GT: Cerebral aneurysms of traumatic origin. *Surg Neurol* 4: 233-239, 1975
- 23) Fujiwara K, Tamaki N, Ohbora Y, Shirakata S, Matsumoto S, Sakamoto K, Kobayashi N: [Three cases of intracranial traumatic aneurysms]. *Traumatology* 7: 377-380, 1976 (Jpn)
- 24) Funahashi K, Mishima T, Hayashi S, Kishi M, Oka M: [Traumatic aneurysm of intracranial portion of the internal carotid artery. Report of a case in which the development of aneurysm was documented by several carotid angiographies]. *No Shinkei Geka* 5: 619-625, 1977 (Jpn, with Eng abstract)
- 25) Funakoshi T, Tsuchiya J, Sakai N, Yamada H, Sakata K: [Peripheral arterial aneurysm of the brain occurring after brain abscess extirpation and healing spontaneously. Report of a case and review of the literature]. *No Shinkei Geka* 4: 405-410, 1976 (Jpn, with Eng abstract)
- 26) Goald HJ, Ronderos A: Traumatic perforation of the intracranial portion of the internal carotid artery with eleven-day survival. Case report. *J Neurosurg* 18: 401-404, 1961
- 27) Handa H, Handa J, Iwayama K, Teraura T, Kikuchi H, Kako M, Furuse S: [Traumatic aneurysm of the extradural portion of the internal carotid artery: report of four cases]. *No To Shinkei* 19: 1063-1072, 1967 (Jpn, with Eng abstract)
- 28) Handa J, Shimizu Y, Matsuda M, Handa H: Traumatic aneurysm of the middle cerebral artery. *AJR Am J Roentgenol* 109: 127-129, 1970
- 29) Higazi I, El-Banhawy A, El-Nady F: Importance of angiography in identifying false aneurysm of the middle meningeal artery as a cause of extradural hematoma. Case report. *J Neurosurg* 30: 172-176, 1969
- 30) Holmes B, Harbaugh RE: Traumatic intracranial aneurysms: a contemporary review. *J Trauma* 35: 855-860, 1993
- 31) Ide Y, Wakuta Y, Orita T, Aoki H: [A case of iatrogenic traumatic intracranial aneurysm]. *No Shinkei Geka* 15: 1353-1359, 1987 (Jpn, with Eng abstract)
- 32) Ito H, Hanyu T, Fujii H, Shima T, Yamamoto S: [Traumatic aneurysm of anterior cerebral artery: in reference to the role of cerebral falx]. *No To Shinkei* 27: 787-793, 1975 (Jpn, with Eng abstract)
- 33) Jackson FE, Augusta FA, Sazima HJ, DeLave DP, Whiteley RH: Head injury and delayed epistaxis: report of case of rupture of traumatic aneurysm of internal carotid artery due to grenade fragment wound received in Vietnam conflict. *J Trauma* 10: 1158-1167, 1970
- 34) Jakobsson KE, Carlsson C, Elfverson J, von Essen C: Traumatic aneurysms of cerebral arteries. A study of five cases. *Acta Neurochir (Wien)* 71: 91-98, 1984
- 35) Jenkins JR, Dadsetan MR, Sener RN, Desai S, Williams RG: Value of acute-phase angiography in the detection of vascular injuries caused by gunshot wounds to the head: Analysis of 12 cases. *AJR Am J Roentgenol* 159: 365-368, 1992
- 36) Kamijyo Y, Namba A, Handa J, Handa H: [Posttraumatic pial artery aneurysm: report of a case followed by repeat angiographies and verified at surgery and by histology]. *No To Shinkei* 20: 965-970, 1968 (Jpn, with Eng abstract)
- 37) Kieck CF, de Villiers JC: Vascular lesions due to transcranial stab wounds. *J Neurosurg* 60: 42-46, 1984
- 38) Komiyama M, Yasui T, Yagura H, Fu Y, Nagata Y: Traumatic carotid-cavernous sinus fistula associated with an intradural pseudoaneurysm: a case report. *Surg Neurol* 36: 126-132, 1991
- 39) Kuhn RA, Kugler H: False aneurysms of the middle meningeal artery. *J Neurosurg* 21: 92-96, 1964
- 40) Lam CH, Montes J, Farmer JP, O'Gorman AM, Meagher-Villemure K: Traumatic aneurysm from shaken baby syndrome: case report. *Neurosurgery* 39: 1252-1255, 1996
- 41) Laurent JP, Cheek WR, Mims T, McCluggage CW: Traumatic intracranial aneurysm in an infant: case report and review of the literature. *Neurosurgery* 9: 303-306, 1981
- 42) Liu MY, Shih CJ, Wang YC, Tsai SH: Traumatic intracavernous carotid aneurysm with massive epistaxis. *Neurosurgery* 17: 569-573, 1985
- 43) Marubayashi T, Kaku M, Yoshida A, Matsukado Y: [Traumatic aneurysm of the frontopolar artery developed after evacuation of the subdural effusion in a 6-month-old girl]. *No Shinkei Geka* 3: 177-183, 1975 (Jpn, with Eng abstract)
- 44) McCormick WF, Beals JD: Severe epistaxis caused by ruptured aneurysm of the internal carotid artery. *J Neurosurg* 21: 678-686, 1964
- 45) Meguro K, Rowed DW: Traumatic aneurysm of the posterior inferior cerebellar artery caused by fracture

- of the clivus. *Neurosurgery* 16: 666-668, 1985
- 46) Menezes AH, Graf CJ: True traumatic aneurysm of anterior cerebral artery. Case report. *J Neurosurg* 40: 544-548, 1974
 - 47) Miyahara S, Cheng CL, Kitamura K: [Intracranial aneurysm due to arterial injury during surgery. Case report]. *No Shinkei Geka* 5: 991-994, 1977 (Jpn, with Eng abstract)
 - 48) Miyazaki S, Ohmori H, Munekata K, Fukushima H, Kamata K: [Spontaneous healing of traumatic aneurysm occurring after brain tumor removal]. *No Shinkei Geka* 9: 531-537, 1981 (Jpn, with Eng abstract)
 - 49) Moore D, Budde RB, Hunter CR, Mayfield FH: Massive epistaxis from aneurysm of the carotid artery. *Surg Neurol* 11: 115-117, 1979
 - 50) Nagasawa S, Inuzuka N, Sato S, Ban S, Chokyu M, Yamamoto T, Ogata M: [Traumatic pseudo-aneurysm]. *Traumatology* 7: 373-376, 1976 (Jpn)
 - 51) Nakamura T, Matsuoka Y, Nishimura S: [Traumatic cerebral aneurysm showing remarkable extravasation into the lateral ventricle. Report of a case in an infant]. *No Shinkei Geka* 5: 371-378, 1977 (Jpn, with Eng abstract)
 - 52) Nakstad P, Nornes H, Hauge HN: Traumatic aneurysms of the pericallosal arteries. *Neuroradiology* 28: 335-338, 1986
 - 53) Noterman J, Flament-Durand J, Hermanus N, Brotschi J: Traumatic aneurysm of the anterior cerebral artery associated with a contralateral carotid-cavernous fistula: A case report. *Neurosurgery* 17: 807-810, 1985
 - 54) Paillas JE, Bonnal J, Lavieille J: Angiographic images of false aneurysmal sac caused by rupture of median meningeal artery in the course of traumatic extradural hematomata. Report of 3 cases. *J Neurosurg* 21: 667-671, 1964
 - 55) Parkinson D, West M: Traumatic intracranial aneurysms. *J Neurosurg* 52: 11-20, 1980
 - 56) Paul GA, Show CM, Wray LM: True traumatic aneurysm of the vertebral artery. Case report. *J Neurosurg* 53: 101-105, 1980
 - 57) Paullus WS, Norwood CW, Morgan HW: False aneurysm of the cavernous carotid artery and progressive external ophthalmoplegia after transphenoidal hypophysectomy. *J Neurosurg* 51: 707-709, 1979
 - 58) Petty JM: Epistaxis from aneurysm of the internal carotid artery due to a gunshot wound. *J Neurosurg* 30: 741-743, 1969
 - 59) Pozzati E, Gaist G, Servadei F: Traumatic aneurysms of the supraclinoid internal carotid artery. Report of two cases. *J Neurosurg* 57: 418-422, 1982
 - 60) Rahmat H, Abbassioun K, Amirjamshidi A: Pulsating unilateral exophthalmos due to traumatic aneurysm of the intraorbital ophthalmic artery. Case report. *J Neurosurg* 60: 630-632, 1984
 - 61) Rumbaugh CL, Bergeron RT, Talalla A, Kurze T: Traumatic aneurysms of the cortical cerebral arteries. Radiographic aspects. *Radiology* 96: 49-54, 1970
 - 62) Sadar ES, Jane JA, Lewis LW, Adelman LS: Traumatic aneurysms of the intracranial circulation. *Surg Gynecol Obstet* 137: 59-67, 1973
 - 63) Sakuta Y, Arai S: [Penetrating brain injury and traumatic aneurysm caused by a nail gun]. *No Shinkei Geka* 25: 357-362, 1997 (Jpn, with Eng abstract)
 - 64) Salar G, Mingrino S: Traumatic intracranial internal carotid aneurysm due to gunshot wound. Case report. *J Neurosurg* 49: 100-102, 1978
 - 65) Salzman M, Botero E, Bellis E: Giant posttraumatic aneurysm of the intracranial carotid artery: evolution and regression documented by computed tomography. *Neurosurgery* 16: 218-221, 1985
 - 66) Sasaoka Y, Kamada K, Kanemoto Y, Otsuka H, Sakitani H, Motoyama Y: [Ruptured traumatic aneurysm of the peripheral anterior cerebral artery: study of delayed hemorrhage after closed head injury]. *No Shinkei Geka* 25: 337-344, 1997 (Jpn, with Eng abstract)
 - 67) Schuster JM, Santiago P, Elliott JP, Grady MS, Newell DW, Winn HR: Acute traumatic posteroinferior cerebellar artery aneurysms: report of three cases. *Neurosurgery* 45: 1465-1468, 1999
 - 68) Sedzimir CB, Occleshaw JV, Buxton PH: False cerebral aneurysm. Case report. *J Neurosurg* 29: 636-639, 1968
 - 69) Senegor M: Traumatic pericallosal aneurysm in a patient with no major trauma. Case report. *J Neurosurg* 75: 475-477, 1991
 - 70) Shallat RF, Taekman MS, Nagle RC: Delayed complications of craniocerebral trauma: case report. *Neurosurgery* 8: 569-573, 1981
 - 71) Shigemori M, Shirahama M, Hara K, Tokutomi T, Kawaba T: Traumatic aneurysms of intracranial internal carotid arteries. Case reports. *Neurol Med Chir (Tokyo)* 22: 241-247, 1982
 - 72) Shima T, Uozumi T, Nishimura S, Nishida M, Tao S: [False aneurysm secondary to penetration of the brain through supraorbital wound. Report of a case]. *No Shinkei Geka* 6: 1025-1030, 1978 (Jpn, with Eng abstract)
 - 73) Smith DR, Kempe LG: Cerebral false aneurysm formation in closed head trauma. *J Neurosurg* 32: 357-359, 1970
 - 74) Smith KR, Bardenheier JA: Aneurysm of the pericallosal artery caused by closed cranial trauma. *J Neurosurg* 29: 551-554, 1968
 - 75) Spetzler RF, Owen MP: Extracranial-intracranial arterial bypass to a single branch of the middle cerebral artery in the management of a traumatic aneurysm. *Neurosurgery* 4: 334-337, 1979
 - 76) Steinmetz H, Heiß E, Mironov A: Traumatic giant aneurysms of the intracranial carotid artery presenting long after head injury. *Surg Neurol* 30: 305-310, 1988
 - 77) Tani S, Funahashi K, Hashimoto T, Miyashita A, Sanada S: [Traumatic aneurysm of the posterior inferior cerebellar artery]. *No Shinkei Geka* 10: 423-427, 1982 (Jpn, with Eng abstract)
 - 78) Teal JS, Bergeron RT, Rumbaugh CL, Segall HD: Aneurysms of the petrous or cavernous portions of

- the internal carotid artery associated with non-penetrating head trauma. *J Neurosurg* 38: 568-574, 1973
- 79) Tokuno T, Ban S, Shingu T, Yamamoto T: [Traumatic anterior cerebral artery aneurysm difficult to distinguish from congenital cerebral aneurysm: case report]. *No Shinkei Geka* 22: 1073-1076, 1994 (Jpn, with Eng abstract)
 - 80) Tsubokawa T, Kotani A, Sugawara T, Moriyasu N: [Treatment for traumatic aneurysm of the cerebral artery. Identification between deteriorating type and spontaneously disappearing type]. *No Shinkei Geka* 3: 663-672, 1975 (Jpn, with Eng abstract)
 - 81) Uzan M, Cantasdemir M, Seckin MS, Hanci M, Kocer N, Sarioglu AC, Islak C: Traumatic intracranial carotid tree aneurysms. *Neurosurgery* 43: 1314-1322, 1998
 - 82) Voris HC, Basile JXR: Recurrent epistaxis from aneurysm of the internal carotid artery. Case report with cure by operation. *J Neurosurg* 18: 841-842, 1961
 - 83) Wortzman D, Tucker WS, Gershater R: Traumatic aneurysm in the posterior fossa. *Surg Neurol* 13: 329-332, 1980
 - 84) Yamaura A, Makino H, Hachisu H, Takemiya S: Secondary aneurysm due to arterial injury during surgical procedures. *Surg Neurol* 10: 327-333, 1978
 - 85) Yokota H, Tazaki H, Murayama K, Shimura T, Higuchi H, Yajima K, Nakazawa S: [Traumatic intracranial aneurysms. Discussion about ninety-four cases including five of our own]. *No Shinkei Geka* 11: 521-528, 1983 (Jpn, with Eng abstract)
 - 86) Yonas H, Dujovny M: "True" traumatic aneurysm of the intracranial internal carotid artery: case report. *Neurosurgery* 7: 499-502, 1980

Address reprint requests to: M. Komiyama, M.D., Department of Neurosurgery, Osaka City General Hospital, 2-13-22 Miyakojima-Hondori, Miyakojima-ku, Osaka 534-0021, Japan.